

Protective effect of huangjingzanyu capsule on cyclophosphamide-induced oligoasthenozoospermia in rats

C.L. Zheng^{1,2}, Q. Wang^{1#}, Y.W. Zhou², M. Jiang³, B. Zhu¹, J. Yan¹, Y. Tang¹, J.Z. Li¹, J. Wang¹, Y. F. Zheng^{1*}

¹Beijing University of Chinese Medicine, Beijing 100029, China

²Beijing Gulou Hospital of Traditional Chinese Medicine, Beijing 100009, China

³Third Affiliated Hospital, Beijing University of Chinese Medicine, Beijing 100029, China

Received December 12, 2015; Revised February 26, 2016

To investigate the protective effect of Huangjingzanyu Capsule on cyclophosphamide-induced oligoasthenozoospermia model in rats. Testicular damage was induced by cyclophosphamide to make the oligoasthenozoospermia model. The expression of testis-related genes in mRNA and protein level was detected by RT-PCR and Western-blot, and the histopathological changes of the testes were analyzed. Huangjingzanyu Capsule increased Bcl-2 protein and mRNA in testis of the rat ($P < 0.05$), and decreased the expression of Bax and Caspase3 protein and mRNA ($P < 0.05$). The pathological changes of testicular tissue injury of Huangjingzanyu Capsule group were significantly improved compared with cyclophosphamide group ($P < 0.05$). Huangjingzanyu Capsule has a protective effect on cyclophosphamide-induced testis injury in rats, and its mechanism is related to improving the expression of Bcl-2 protein and mRNA in testes and decreasing the expression of Bax, Caspase3 protein and mRNA

Keywords: Huangjingzanyu Capsule; Oligoasthenozoospermia; Mechanism of action

INTRODUCTION

Huangjingzanyu Capsule as the first specialized spermatogenic prescription for the treatment of male infertility, made by lifetime professor Wang Qi of Beijing University of Chinese Medicine, who is one of the founders of TCM andrology. Previous studies have found that Huangjingzanyu Capsule has a better therapeutic effect on oligoasthenozoospermia, but its molecular mechanism is unclear. In this study, cyclophosphamide was used to prepare the oligospermia model and analyze histopathological damage of the testis through detecting the protective effect of Huangjingyanyu Capsule on testis by RT-PCR and Western blot.

MATERIALS AND METHODS

Main experimental equipment

Western Blot electrophoresis apparatus (Bio-Rad); Genequant spectrophotometer (GE company); Nanodrop High-precision nucleic acid spectrophotometer (Thermo Fisher); ABI 7500 real-time fluorescence quantitative PCR instrument (Life); optical microscope: Japan Olympus company, product model: BX50; transmission electron microscope: Japan JEOL company, product model: JEM-1230..

Main Chinese patent medicine and drugs

Huangjingyanyu Capsule: Shanghai New Asia Pharmaceutical Hanjiang Co. Limited, lot number: 120603; Levocarnitine: Northeast Pharmaceutical Group Shenyang First Pharmaceutical Co., Ltd., lot number: 121001; Cyclophosphamide (CP): Shanxi Pude Pharmaceutical Co., Ltd., lot number: 04121003. The Chinese patent medicine and drugs above is suspended in 0.5% CMC in reserve before use.

Main reagents

Complete Protease Inhibitor Cocktail Tablets (Roche); ECL developing solution (Perkin-Elmer Life Sciences); PVDF film (MerckMillipore company); Trizol (Life Invitrogen company); 2X Mltra SYBR Mixture (CW0958) (Beijing Kangwei Century Co., Ltd.); Mixture (Promega company); DEPC (sigma company); Caspase-3 antibody (sc-7148, Santa Cruz); BAX (B-9) antibody (sc-7480, Santa Cruz); BCL-2 antibody (sc-7382, Santa Cruz); β -actin antibody (Tianjin Sungene Biotech); protein marker (Thermo Scientific).

Experimental methods

1. Grouping and administration methods: A total of 40 SD rats were randomly divided into four groups: normal group, model group, Huangjingzanyu Capsule group, and Levocarnitine control group, with 10 rats in each group. The rats were given adaptive feeding for three days. Normal

* To whom all correspondence should be sent:
E-mail: yanfei_z@163.com

group (NS): equal volume of normal saline instead of CP was given by intraperitoneal injection for five days, and normal saline was given by gastric perfusion from the sixth day for two weeks. Continuous gastric perfusion for 2 weeks. Model group (CP): CP of 35mg / kg was given by intraperitoneal injection for 5 days, and normal saline was given by gastric perfusion from the 6th day for two weeks. Huangjingzanyu Capsule group (HJZYC): CP of 35mg / kg was given by intraperitoneal injection for five days, and Huangjingzanyu Capsules of 1.24g / kg • d were given by gastric perfusion from the sixth day for two weeks. Levocarnitine group (Levocarnitine): CP 35mg/kg was given by intraperitoneal injection for five days, and Levocarnitine of 2.1ml / kg • d was given by gastric perfusion from the sixth day for two weeks. After 24 hours of the last administration, all the rats were anesthetized with chloral hydrate, and the testes and epididymis were quickly removed refrigerated in -80°C environment.

2. Real-time PCR was used to detect the contents of Caspase-3, Bcl-2 and Bax in testes.

3. Western Blot was used to detect the expression of Caspase-3, Bcl-2 and Bax in the testis.

4. Pathological detection of testicular tissue.

Six rats in each group were taken out, and their left testicular tissue was given HE staining for histopathological examination with light microscope. The spermatogenic cell lesions in

testicular seminiferous tubules were main observed and semi-quantitative Grading scale (Table 1) for testicular lesions was made. Two rats in each group were randomly selected to take two to three pieces of testicular tissue (about 0.5mm) to perform transmission electron microscopy.

Statistical methods

All measurement data were expressed as mean ± standard deviation ($\bar{x} \pm s$). Nonparametric rank sum test was used to compare the testicular lesions between each two groups, and statistics software SPSS 20.0 was used to perform T test with $P < 0.05$ meaning statistical significance between each group.

RESULTS

Caspase-3, Bcl-2 and Bax protein, expression results of mRNA

The results showed that the expression level of Caspase-3 protein and mRNA in the testicular tissue of model group was significantly higher than that of the normal group ($P < 0.05$). The expression level of Caspase-3 protein and mRNA in Huangjingzanyu Capsule group and Western medicine control group was significantly lower than that in model group ($P < 0.05$), suggesting that Huangjingzanyu Capsule and Levocarnitine had the effect on reducing the expression of Caspase-3 protein and mRNA. (seen in Figure 1 and Figure 2).

Table 1. Testicular grading criteria

Score	Pathological grading	Testicular lesions
0	-	Testicular seminiferous tubules were normal without obvious lesions.
1	+	Spermatogenic cells arranged disorder in testicular individual seminiferous tubule, part of the cell being swelling, degenerated, and sperm cells decreased.
2	++	Many spermatogenic tubules in testes underwent mildly atrophy, spermatogenic cells arranged in disorder, cell swelled and degenerated, and sperm cells significantly reduced.

Table 2. Changes of testicular lesion of each group.

Group	Lesion degree			Average rank
	-	+	++	
NS	6	0	0	8.50
CP	0	3	3	30.40#
HJZYC	4	1	1	13.80*
Levocarnitine	2	3	1	17.50*

Note: Compared with model group, * $P < 0.05$; Compared with normal group, # $P < 0.05$

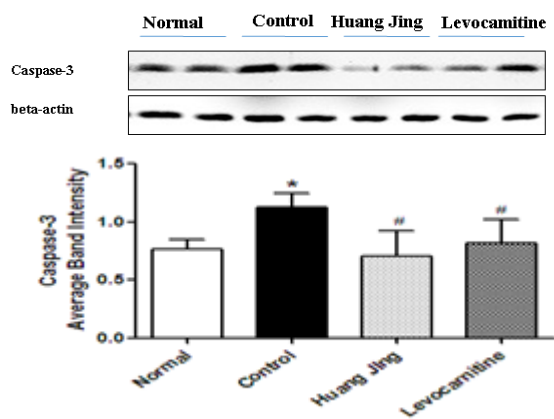


Fig. 1. Effect of Huangjingzanyu Capsule on the expression of Caspase - 3 protein in testicular tissue of Rats. Note: Compared with normal group, * $P < 0.05$; Compared with model group, # $P < 0.05$.

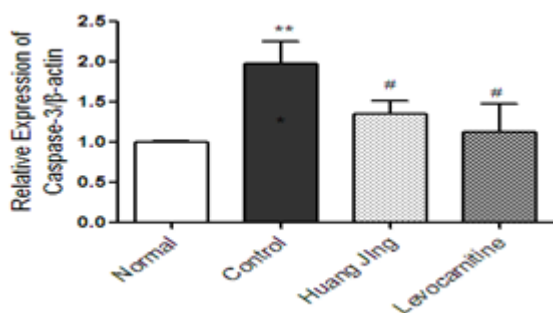


Fig. 2. Effect of Huangjingzanyu Capsule on the expression of Caspase - 3 mRNA in testicular tissue of Rats. Note: Compared with normal group, * $P < 0.05$; Compared with model group, # $P < 0.05$.

For the expression of Bcl-2 protein, the expression level of Bcl-2 protein and mRNA in the testis of CP group was significantly lower than that of NS group ($P < 0.05$). The expression level of Bcl-2 protein and mRNA in HJZYC group and levocarnitine group was significantly higher than that in CP group ($P < 0.05$), suggesting that Huangjingzanyu Capsule and Levocarnitine had the effect on increasing the expression of Caspase-3 protein and mRNA. While the expression level of Bax protein and mRNA in the testicular tissue of CP group was significantly higher than that in NS group ($P < 0.05$). The expression level of Bax protein and mRNA in HJZYC group and levocarnitine group was significantly lower than that in CP group ($P < 0.05$), suggesting that Huangjingzanyu Capsule and Levocarnitine all had the effect on reducing the expression of Bax protein and mRNA. (seen in Figure 3 and Figure 4).

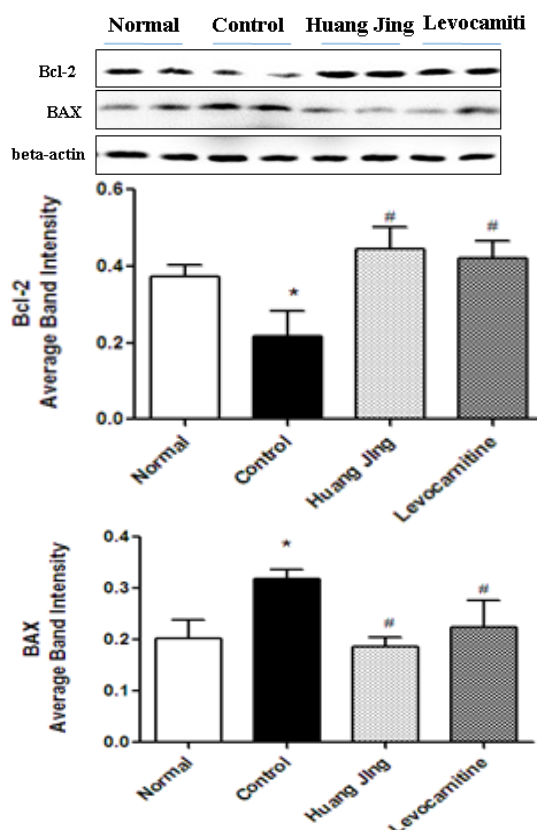


Fig. 3. Effect of Huangjingzanyu Capsule on the expression of Bcl-2 and Bax protein in testicular tissue of Rats. Note: Compared with NS, * $P < 0.05$; Compared with CP, # $P < 0.05$.

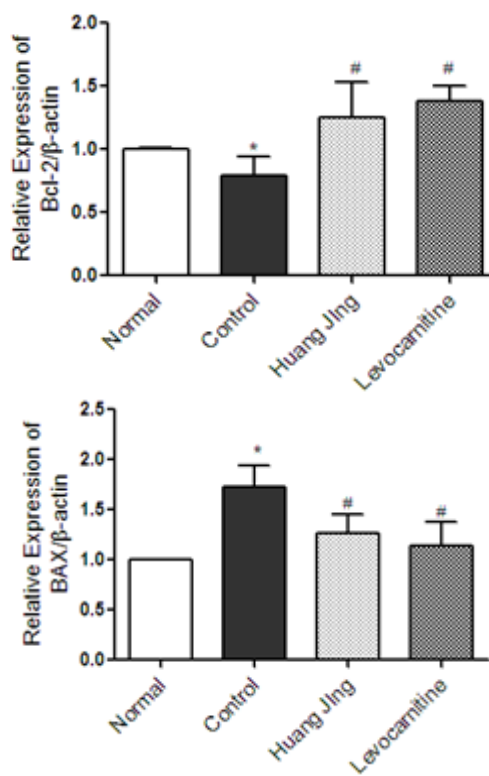


Fig. 4. Effect of Huangjingzanyu Capsule on the expression of Bcl-2 and Bax mRNA in testicular tissue of Rats. Note: Compared with NS, * $P < 0.05$; Compared with CP, # $P < 0.05$.

Histopathological changes of the testis

After the model was established, the testicular lesions of CP group were more serious than those of NS group ($P < 0.05$). After medication intervention, HJZYC group and Levocarnitine group improved significantly ($P < 0.05$). (more details seen in Table 2, Figure 5 - Figure 8)

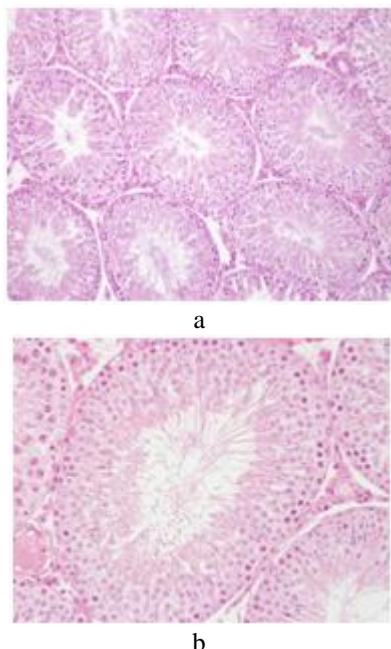


Fig. 5. Pathological section of rat testis in NS group: a) Pathological section of rat testis in NS group (HE×200); b) Pathological section of rat testis in NS group (HE×400)

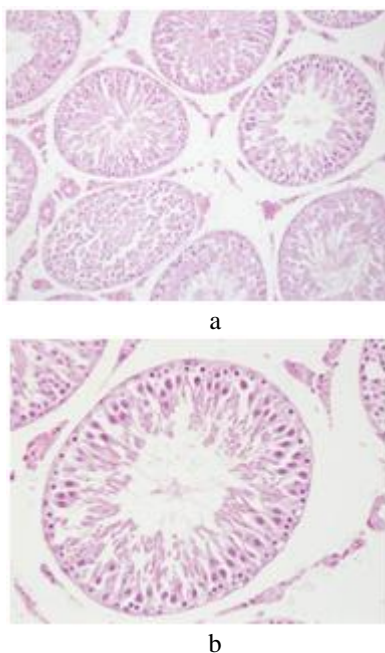


Fig. 6. Pathological section of rat testis in CP group: a) Pathological section of rat testis in CP group (HE×200); b) Pathological section of rat testis in CP group (HE×400)

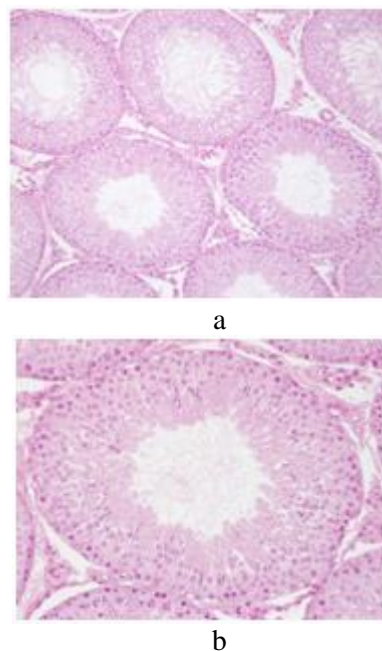


Fig. 7. Pathological section of rat testis in HJZYC group: a) Pathological section of rat testis in HJZYC group (HE×200); b) Pathological section of rat testis in HJZYC group (HE×400)

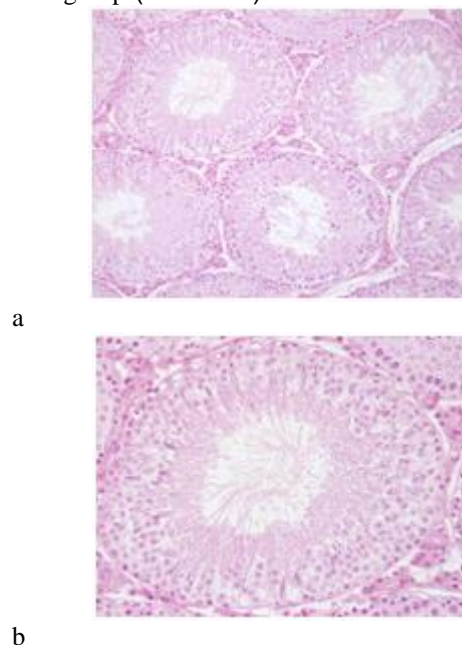


Fig. 8. Pathological section of rat testis in Levocarnitine group: a) Pathological section of rat testis in Levocarnitine group (HE×200); b) Pathological section of rat testis in Levocarnitine group (HE×400)

Changes of ultrastructure of testicular tissue

Spermatogenic cells and supporting cells were observed in the epithelium of seminiferous tubules in NS group. All levels of structure of Sperm cells were normal, and a lot of sperms were formed in the lumen. Cell membrane is mooth and complete with the existence of mitochondria and lysosomes. The mitochondria were round or rod with tubular ridge.

Supporting cell base was close to the basement membrane with oval nuclear, notch, and significant nucleolus (Figure 9). In the CP group, the basal membrane of the seminiferous tubule was irregular with widened gap or even local avulsion, defect, and fracture. The junction between supporting cell and spermatogonia widened and vacuolized. Mitochondria swelled showing polymorphic change with common ring and dumbbell shapes, and disappearance or vacuolization of mitochondrial ridges. Muscle-like cell shrunk with long oval shape (Figure 10). After the intervention of Huangjingzanyu Capsule, the base of the supporting cells was close to the basement membrane. The mitochondria of the spermatogenic cells and supporting cells were slightly swollen. The ridge of mitochondria ruptured slightly and partially vacuolated, but the whole condition was improved compared with the CP group (Figure 11) After the intervention of the Levocarnitine group, the support cells were round with marked nucleolus, and mitochondria and lysosomes were seen in the cytoplasm. The mitochondria were elliptic or round, slightly swollen, and some mitochondria decreased and vacuolated. The microtubule sperm tail was seen of "9 +2" structure (Figure 12).




Fig. 9. Ultrastructure of NS group, $\times 12000$

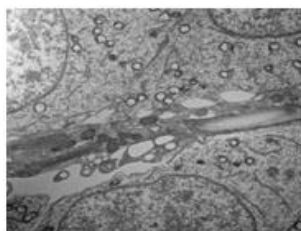


Fig. 10. Ultrastructure of CP group, $\times 8000$

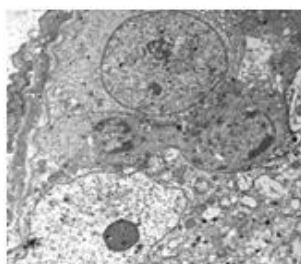


Fig. 11. Ultrastructure of HJZYC group, $\times 8000$

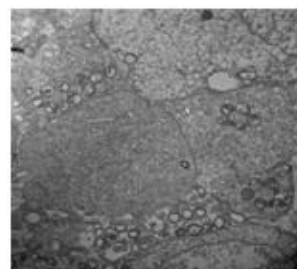


Fig. 12. Ultrastructure of Levocarnitine, $\times 8000$

DISCUSSION

The normal process of spermatogenesis requires the maintenance of the balance between cell proliferation and differentiation and apoptosis. Studies have shown that in the process of spermatogenesis, the body removes spermatogenic cells that are damaged or the chromosomes in them are abnormal through the germ cell apoptosis to strictly control the optimal number of spermatogenic cells and supporting cells and to ensure the normal number and quality of sperm differentiation and maturity [1]. The conditions such as environmental factors, living habits, pathological factors, physical and chemical factors, reproductive system infections, chronic inflammation, varicocele and other reasons can cause deterioration of testicular spermatogenic, and adverse effects of the testicular germ cell apoptosis or apoptosis-related genes[2], leading to spermatogenesis damage and the increase of all levels of apoptosis of spermatogenic cells (including sperm), resulting in sperm production increase, quality decrease, apoptosis index increase, and as an important result of less weak spermatogenesis [3], which is the important pathological step and mechanism of oligoasthenozoospermia. Studies show that 75% of the sperms die through apoptosis [4]. The mechanism of apoptosis during spermatogenesis has become one of the hotspots in the research of testicular biology [5].

So far, three apoptosis pathways have been identified: the death receptor pathway, the endoplasmic reticulum signaling pathway, and the mitochondrial pathway [8]. In mitochondrial pathway, cells are exposed to DNA damage, hypoxia, drug action and etc., and the mitochondrial permeability changes, membrane potential decrease and cytochrome C release, which activates Caspase-9 and Caspase-3 leading to apoptosis. Bcl-2 family is the main regulatory gene to prevent apoptosis cascade reaction process, through the regulation of transport and membrane permeability of endoplasmic reticulum nuclear matter inside and outside to prevent the release of cytochrome c. Bcl-

2 protein is a kind of membrane integral protein. The quantitative results show that the expression of Bcl-2 protein decreases with the increase of apoptosis rate in normal testis cells of rats. Bcl-2 gene family includes two major categories: genes that inhibits apoptosis such as Bcl-2 and genes that promotes apoptosis such as Bax. Bax is located in the cytoplasm and is activated by the apoptotic signal. Bax can form dimer or multimerize and insert into the mitochondrial membrane, leading to the decrease of mitochondrial membrane potential and the release of cytochrome c. The equilibrium state of intracellular Bcl-2 and Bax determines whether the cell ultimately survives or dies [9]. Studies have reported that when spermatogenic cells of kidney-yang deficiency rats undergo apoptosis, at the same time, Bax gene expression increases and Bcl-2 gene expression decreases, in order to promote spermatogenic cell apoptosis [10]. Chinese medicinal Shengjing Decoction can significantly improve the ratio of Bcl-2 / Bax, inhibit spermatogenic cell apoptosis, and promote cell proliferation [11].

This study has found that, after CP modeling, the expression of Bcl-2 protein and mRNA of testicular tissue in CP rats decreases, while the expression of Bax, Caspase3 protein and mRNA increases, indicating that CP can cause testicular spermatogenic dysfunction through apoptosis, and then result in less weak Spermatogenesis. After the intervention of Huangjingzanyu Capsule and Levocarnitine, the expression of Bcl-2 protein and mRNA in the testicular tissue of rats increases significantly, and the expression of Bax and Caspase3 protein and mRNA decreased significantly, suggesting that through increasing significantly the expression of Bcl-2 protein and mRNA, Huangjingzanyu Capsule can decrease the expression of pro-apoptotic gene Bax protein and mRNA to inhibit the apoptosis of spermatogenic cells, and significantly reduce the activity of Caspase-3, a public apoptotic factor, which plays a pivotal role in the apoptosis process to inhibit spermatogenic cell apoptosis, promote sperm production, and improve semen quality.

CONCLUSION

In HJZYC group and levocarnitine group the expression level of Bcl-2 protein and mRNA of

testicular tissue of rats increases, while the expression level of Bax, Caspase3 protein and mRNA decreases. The degree of testicular pathological damage in CP group is significantly higher than that in NS group ($P < 0.05$), indicating that the modeling is successful, and the gap between support cells and spermatogonia widens, breaks and ruptures. Mitochondria swells or vacuolizes. After the intervention of Huangjingzanyu Capsule, the condition improves significantly. the seminiferous tubule epithelium does not change significantly. There are more spermatogenic cells and they arrange more regularly. Testicular stroma is denser, and the stromal cells arrange more evenly. Mitochondria in spermatogenic and supporting cells are slightly swollen, and mitochondrial ridge is slightly ruptured and partially vacuolated, but the overall condition improved compared with CP group.

Acknowledgements: This Research was supported by Fundamental Research Project of Beijing University of Chinese Medicine(NO.2015-JYB-JSMS010) and National Natural Science Foundation Project (NO. 81503584).

REFERENCES

- 1.R.J. Blanco, G.C. Martinez, *Cell Prolif*, **29**(1), 13 (1996).
- 2.E. Pishavar, M. Shafiei, S. Mehri, *Drug Chem Toxicol*, **18** (2017).
- 3.M.Wu, C. Pan, Z. Chen, *Environ Sci Pollut Res Int*, **12** (2017).
- 4.D.T. Carrell, B.R. Emery, S. Hammoud, *Hum Reprod Update*, **13**(3), 313 (2007).
- 5.Y.F. Wang, *The Sixth National Conference of Reproductive Medicine Special Issue*, (2012).
- 6.X.W. Cao, C.Y. Li, C.W. Yuan, *Chinese J Sex Sci*, **20**(2), 51 (2011).
- 7.Q. Michele, M.B. Rosiane, C. Carla, *Eur J Obstet Gynecol Reprod Biol*, **167**, 47 (2013).
- 8.D.A. Ferrington, T.N. Tran, L. Kathleen, *Exp Eye Res*, **83**, 638 (2006).
- 9.M. Ghoneum, M. Matsuura, M. Braga, *Int J Oncol*, **33**(3), 533 (2008).
- 10.X. Li, J. Li, G.W. Fu, *Chengde Med Coll*, **2**, 118 (2007).
- 11.J. Mohammadian, M. Sabzichi, O. Molavi, *Asian Pac J Cancer Prev*, **17**, 11 (2016).
- 12.L. Wang, D.Chen, Z. Min, *Zhongguo Zhong Xi Yi Jie He Za Zhi*, **34**(5), 602(2014).